Application of Magnetic Resonance Imaging and Computer Vision Technologies for Analysis of Knee Articular Cartilage Degeneration

Artjoms Suponenkovs[1], Ardis Platkajis[2], Zigurds Markovics[1]

[1]*Faculty of computer science and information technology, Riga Technical University, Riga, Latvia*

[2]*Medical Academy of Latvia, Riga, Latvia*

ABSTRACT

Introduction: There is a growth in the number of people with osteoarthritis. Consequently, the analysis of knee articular cartilage degeneration by magnetic resonance imaging data is very important. The magnetic resonance imaging data of a knee contains a lot of information. Unfortunately, a radiology technologist who uses simple (grayscale) images can analyze only a small part of knee data. The aim of the proposed methods is to provide more information about knee articular cartilage.

Materials and Methods: This paper proposes methods for visualization of knee cartilage, segmentation of knee tissues and analysis of cartilage changes.

Results: The experimental part contains the results and descriptions of visualization, segmentation and analysis methods.

Conclusions: The proposed methods and data obtained from cartilage experiments can be useful for diagnosing osteoarthritis, which will allow starting treatment earlier and therefore reducing the risk of cartilage destruction.

Keywords: medical imaging; knee-joint; computer vision; osteoarthritis; image pre-processing; magnetic resonance imaging; image segmentation; tissue analysis; DICOM.

INTRODUCTION

Today there is a remarkable growth in the number of people with osteoarthritis(OA)[1] in response to decreasing human physical activity. In osteoarthritis, the knee cartilage becomes thin, worn or torn [2]. Therefore, the analysis of knee articular cartilage degeneration by magnetic resonance imaging data is very important. Magnetic resonance imaging (MRI) is used to analyze and display knee articular cartilage. A knee MRI scanning result contains a lot of information. A radiology technologist which uses simple (grayscale) images can see and analyze only a small part of the knee MRI scanning information. This makes it very difficult for a technologist to make an early osteoarthritis diagnosis. The aim of this work is to provide more information about the soft tissues of the knee, using computer vision technologies. Computer vision technologies make it possible to analyze all of the knee MRI scanning information. This analysis can be helpful for early diagnosis of osteoarthritis.

Ramifications of OA are very dangerous: limiting the range of movement, pain and other problems. It is moreover important to start treatment of OA as soon as possible. The early OA detection gives a chance to completely cure osteoarthritis. The early OA detection is rendered difficult for a radiology technologist which uses simple (grayscale) images. The aim of this work is to help the radiology technologist make the right OA diagnosis with the help of computer vision technologies. To reach this aim, it is useful to solve three problems (Fig. 1): the visualization of a knee MRI scanning result - displaying the important information about knee cartilage for radiology technologist; the automatic/semi-automatic tissue segmentation - knee tissue segmentation for further analysis; the tissue analysis - get the quantitative information about the condition of knee tissues.

Fig. 1. Flowchart of analysis of knee articular cartilage degeneration

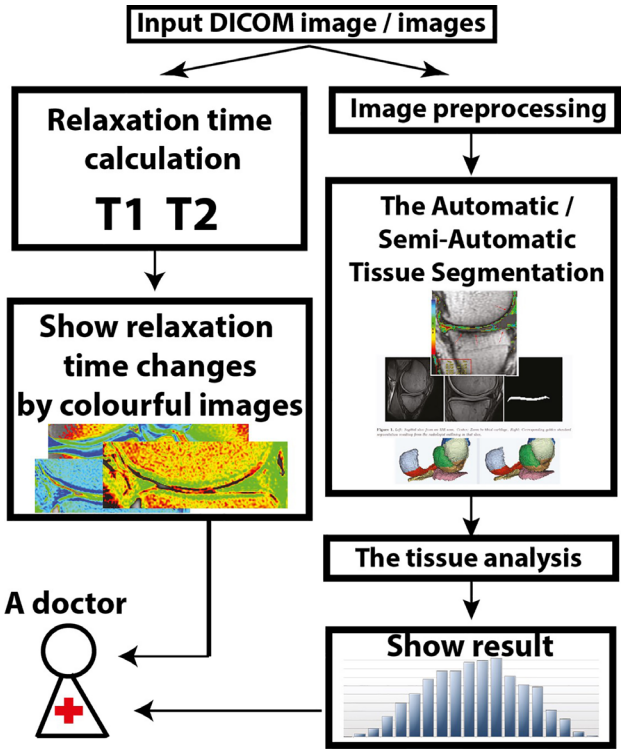

MATERIALS AND METHODS

Usually the result of MRI scanning is saved in the DICOM (Digital Imaging and Communications in Medicine) file. This file contains a knee image of signal intensities. This image of signal intensities is the main source of information for tissue analysis [3]. The range of signal intensity values is very wide: from 0 to 6 000 (sometimes reaching 15 000). However, this image has to be converted in order to display signal intensities on computer. The result of this conversion is a grayscale image. Grayscale image values are in the range from 0 to 255. Therefore, the grayscale image shows only a small part of knee MRI scanning information. However, it is possible to show more information about knee tissues by using color image. Color image values are in the range from 0 to 16 777 215. It is important to choose the most appropriate color model, keeping in mind the human perception of color [4]. One of the appropriate color systems is hue-saturation-value (HSV) color model. Special visualization methods of a knee MRI scanning result can be useful for displaying signal intensities.

The automatic / semi-automatic tissue segmentation is an important and complicated task. Tissue segmentation makes it possible to analyze different tissues. This segmentation can be helpful for 3D reconstruction of knee tissue. Today there are many methods for segmentation: k-means clustering [5], watershed segmentation [6], active contour segmentation [7] and other methods. It is possible to separate different tissues in an image, by using a combination of these methods. Each tissue type has a unique texture. Therefore, knee tissue segmentation results could be improved by textural tissue features analysis. Textural tissue analysis can be performed by analyzing spatial frequencies, statistical characteristics and structural elements.

After tissue segmentation, it is possible to make separate tissue analysis that is based on physical and biochemical tissue features, biological information of knee structure. This type of analysis identifies the tissue anomalies, pathology. Therefore, it is possible to define knee articular cartilage degeneration by using quantitative information about knee tissues condition.

The are 5 grades of OA [8,9] by Outerbridge classification. Each grade has a unique visual symptom:

0) Normal cartilage;
1) Cartilage softening;
2) Loss of <50% cartilage thickness;
3) Loss of > 50% cartilage thickness;
4) Cartilage loss.

Early diagnosis of OA is very important, since it is necessary to start OA treatment as soon as possible. However, it is hard to detect the first grade (cartilage softening) by MRI. Therefore, we were trying to find additional symptoms of the first grade. It is possible to use additional information about biochemical tissue features. **The first grade has additional MRI symptoms [10]:**

1) Increased proton density (where proton density – is the number of hydrogen resonating protons per unit of volume);
2) Increased T1rho relaxation time (where relaxation time – is the recovery time of the proton spin magnetization after RF exposure);
3) Increased T2 relaxation time.

These symptoms make it possible to detect the first grade.

RELAXATION TIME CALCULATION

MRI scanning result is an image of signal intensities. This scanning result makes it possible to calculate relaxation time. The relaxation time can be calculated by one, two or more MRI images.
The T1 and T2 relaxation times calculation by one MRI image is not precise. However, this approximate method can be useful for relaxation time comparison of different knee tissue segments.
The relaxation times calculation by two MRI images is more precise than the previous method. However, for this method it is necessary to get more scanning information than in the previous method.
The relaxation time calculation by many MRI images allows modulate relaxation process [11]. For this method it is necessary to get 7 or 8 images that display the same knee slice. These images have different TE (T2 relaxation time calculation) or TR (T1 relaxation time calculation) parameters. It is possible to calculate T2 and T1 relaxation time by using partial derivatives and the least square method (1).

$$S(P1,P2) = \sum_{i=1}^{n}(S_i - P1*\exp(\frac{-E_i}{P2})^2 \rightarrow \min$$

$$\begin{cases} \frac{\partial S}{\partial P1} = -2\sum_{i=1}^{n}(e^{\frac{-E_i}{P2}}*(S_i - P1*e^{\frac{-E_i}{P2}}) = 0 \\ \frac{\partial S}{\partial P2} = -\frac{2}{P2^2}*P1*\sum_{i=1}^{n}(e^{\frac{-E_i}{P2}}*(S_i - P1*e^{\frac{-E_i}{P2}})*E_i) = 0 \end{cases}$$

Where:
S – MRI signal,
P1 – initial magnetization (M0),
P2 – relaxation time (T2),
SI – intensity value of image pixel,
TE – Echo Time,
n – Count of images.

Visualization of a knee MRI scanning result
Visualization of a knee MRI scanning result makes it possible to show more information about knee tissues by using color images. The task of visualization is to convert intensity or relaxation time values into the color image. Therefore, each value has an appropriate color. For this purpose, it is possible to use the function (2). This function changes the parameter of a color model (CMP). Change of a parameter depends on the values of intensities or relaxation times.

$$CMP = CR_{MIN} + VALUE * STEP$$

Where CMP – modifiable parameter of color model;
CRMIN – minimal CMP value;
VALUE - value of intensity or relaxation time;
STEP – the ration of CMP range to value range (equation 3).

$$STEP = \frac{CR_{MAX} - CR_{MIN}}{VR_{MAX} - VR_{MIN}}$$

Where CRMAX – maximal CMP value;
VRMAX – maximal visualization value;
VRMIN – minimal visualization value.
The color image of the scanning result depends on the color model. There are 2 color models used in this work. The color model allows converting MRI signal value to color. BGRA model contains 4 components: blue, green, red, alpha. It is not difficult to display the BGRA information on the RGB-screen. However, HSV model is closer to the human perception of color than BGRA model. Therefore, HSV to RGB conversion is required for the visual display of HSV information. HSV model contains 3 components: hue, value, saturation. There are 4 display modes in this work (Fig. 2.).
1) BLUE RED: BGRA model – color range is CRMAX = 500, CRMIN = 0; modifiable parameters (CMP) are blue and red components.
2) FULL HUE: HSV (hue, saturation value) model - color range is CRMAX = 360, CRMIN = 0; modifiable parameters (CMP) is the hue component.
3) BLUE GREEN RED: HSV model – color range is CRMAX = 250, CRMIN = -10; modifiable parameters (CMP) is hue.
4) GREEN RED: HSV model – color range is CRMAX = 150, CRMIN = -30; CMP is hue.

Fig. 2. Display modes of MRI scanning result

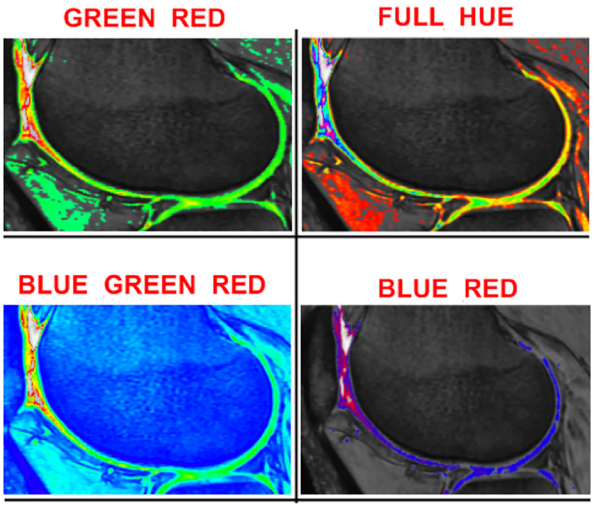

The value range (VRMAX - VRMIN) depends on the power of the MRI magnet. For example:
1) Power of MRI magnet is 1.5 Tesla - range of signal intensities is 0 – 6000;
2) Power of MRI magnet is 3 Tesla – range of signal intensities is 0 – 9000.
After relaxation time calculation, it is possible to get ranges of relaxation times:
1) Range of relaxation time T1 – is 0...6000 ms (3 Tesla);
2) Range of relaxation time T2 – is 0…2000 ms.
Sometimes, it is necessary to show only one type of tissues (for example cartilage), in this case, it is possible to decrease value range. This minimization, in turn, has made it possible to show more information about the proper tissue.

IMAGE PREPROCESSING AND SEGMENTATION OF A KNEE MRI SCANNING RESULT

The image segmentation makes it possible to perform an analysis of knee. However, segmentation is a very complicated task, because MRI image contains a lot of information. Therefore, it is important to remove unnecessary information from MRI image. For this purpose, it is possible to use image preprocessing (Fig.3).
There are two types of image preprocessing used in this work: Perona – Malik filter [12] and Sobel operator. Perona – Malik filter is an anisotropic diffusion that removes high frequency components (noise, small details). This filter has an advantage that it does not remove borders of

Fig. 3. Two types of MRI image preprocessing

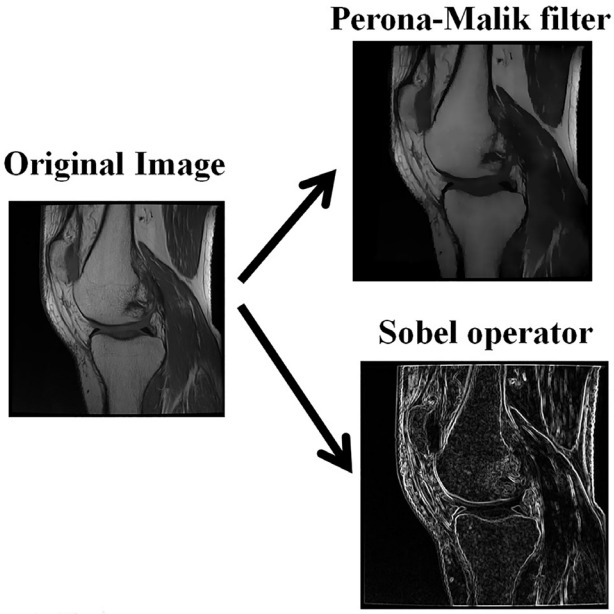

large segments. Therefore, Perona – Malik filter prepares MRI image for further segmentation. The anisotropic diffusion is described with the equation (4):

$$I_t(x,y,t) = div(c(x,y,t)\nabla I(x,y,t))$$

Where
c - Special diffusion coefficient;
I - smoothing image (the level of smoothing of the image depends on the t parameter);
div - divergence;

IT - RESULTING IMAGE.

As shown in Figure 4, combination of two methods (Perona – Malik filter and K-means clustering [13]) provided good segmentation results.
The second segmentation type is watershed segmentation [14]. As shown in Figure 4, this segmentation works well together with Sobel operator. However, the result of watershed segmentation contains a lot of tiny segments. This problem can be solved by using additional information about knee.
Sometimes, it is necessary to improve the accuracy of segmentation. For this reason, knee tissue segmentation results could be improved by textural tissue features analysis. Textural tissue features analysis can be performed by using a co-occurrence matrix [15].

Fig. 4. Two types of MRI image segmentation

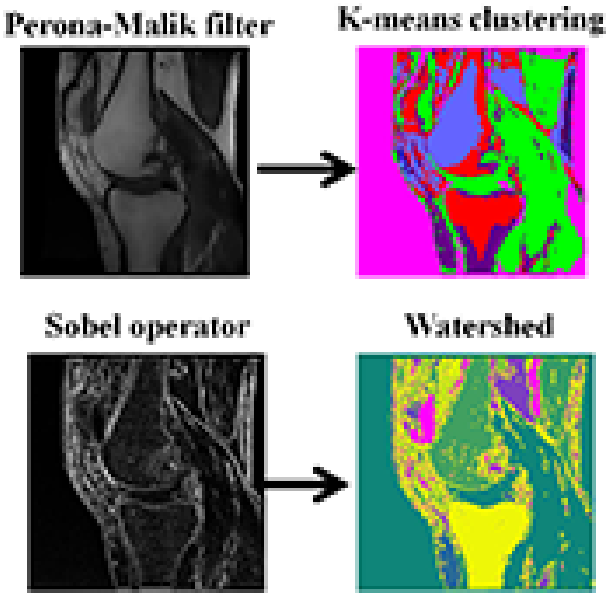

THE TISSUE ANALYSIS

After automatic / semi-automatic tissue segmentation is finished, it is possible to perform knee analysis. The goal of this analysis is to detect the OA symptoms. There are many visual symptoms of OA: synovial effusion, eroded cartilage, narrowed joint space, subchondral bone lesion, osteophyte, inflamed synovium. However, these are symptoms of OA 2-4 grades. The first grade of OA is of most interest in respect to treatment benefits. The first grade is very important because at this stage it is possible to completely cure OA. However, there are no perceptible visual changes of a knee at this stage. Therefore, biochemical changes of a knee must be taken into account. There are some biochemical and physical changes of cartilage tissue at this stage: increase in the water content in cartilage; development of surface fibrillation; destruction of collagen fibers; increase in the T1rho, T2 and proton density. These changes of cartilage tissue have an influence on the intensities of cartilage tissue. For this reason, it is possible to analyze intensities of cartilage tissue by calculating the dispersion (5) and histogram.

$$D = \overline{X^2} - (\overline{X})^2$$

$$\overline{X} = \frac{1}{n}\sum_{i=1}^{n} X_i$$

$$\overline{X^2} = \frac{1}{n}\sum_{i=1}^{n} X_i^2$$

$$\sigma = \sqrt{D}$$

Where

D – Dispersion of cartilage pixel intensities;

– Arithmetic mean of cartilage pixel intensities;

– Arithmetic mean of square cartilage pixel intensities;

n – Pixel count;

σ – Standard deviation.

RESULTS

RESULTS OF VISUALIZATION METHODS

Experiments were performed with special visualization methods, aiming to look for cartilage degeneration by using HSV and BGRA color models. These matching experiments used 5 display modes: MRI original image (monochrome), Blue Red (BGRA model), Full Hue (HSV model), Blue Green Red (HSV model), Green Red (HSV model). The results of these experiments (fig. 5) show that the highest number of observable changes of cartilage has been in HSV and BGRA color models. The Full Hue display mode has the best result because of the wide range of hue values. These experiments were performed using 19 different MRI images.

Fig. 5. Evaluation of visualization methods

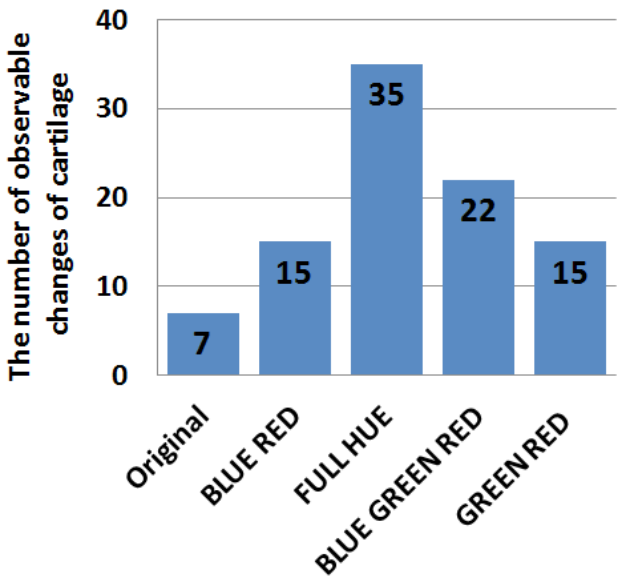

RESULTS OF SEGMENTATION

Experiments were performed with k-means clustering and watershed segmentation (fig. 4). The results showed that the combined use of Perona – Malik filter and k-means clustering provide the most effective tissue segmentation. The results showed that some tissues are difficult to separate from each other. Therefore, additional textural tissue features analysis should be used.

RESULTS OF TISSUE ANALYSIS

The aim of this experiment is to compare the intensity dispersion of healthy and damaged cartilages. For these comparative experiments, proton density (PD) fat-suppressed (FS) MRI sequence was used. The MRI sequence TE and TR parameters have the following values:
1) TE - from 26 to 29;
2) TR - from 2923 to 3170.
The results of cartilage tissue analysis (fig. 6) show that a healthy patient (green color P2 and P5) has lesser standard deviation of cartilage signal intensity values than patients with OA (red color P1, P3, P4, et al.).

Fig. 6. Standard deviation of cartilage pixel intensities

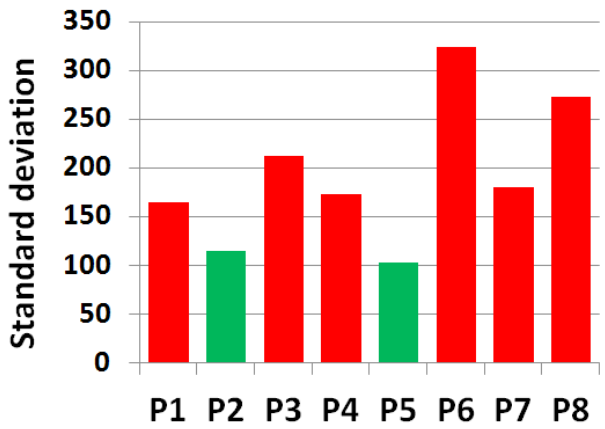

CONCLUSION

Results of visualization methods show that the use of HSV and BGRA model provides the most effective visualization of the cartilage degeneration. Moreover, the Full Hue display mode is the most sensitive to changes in cartilage intensity values. Results of tissue analysis show that the intensity dispersion and intensity standard deviation of cartilage can help with the OA detection. The above-mentioned methods and results can be useful for OA diagnosis, which allows starting treatment earlier and therefore reduces the risk of cartilage destruction.

REFERENCES

1. Ian J. Wallace, Steven Worthington, David T. Felson, et al. Knee osteoarthritis has doubled in prevalence since the mid-20th century. Proc Natl Acad Sci U S A. 2017 Aug 29; 114(35): 9332–9336.

2. Alice Roberts. The complete human body. Penguin Random House. 2016.

3. Mario Mustra, Kresimir Delac, Mislav Grgic. Overview of the DICOM Standard. 50th International Symposium ELMAR-2008, 10-12 September 2008, Zadar, Croatia.

4. Michael A Webster. Human colour perception and its adaptation. Computation in Neural Systems 7 (1996) 587–634.

5. Kalpana Shrivastava, Neelesh Gupta, Neetu Sharma. Medical Image Segmentation using Modified K Means Clustering. International Journal of Computer Applications. Volume 103 – No 16, October 2014.

6. Dibyendu Goshal, Pinaki Pratim Acharjya. MRI Image Segmentation Using Watershed Transform. International Journal of Emerging Technology and Advanced Engineering. ISSN 2250-2459, Volume 2, Issue 4, April 2012.

7. Amira Ben Rabeh, Faouzi Benzarti, Hamid Amiri. Segmentation of Brain MRI Using Active Contour Model. National Engineering School of Tunis (ENIT), Signal, Image and Technology Information (LR-SITI), Manar, Tunisia, 2016.

8. Helmtrud I. Roach and Simon Tilley. The Pathogenesis of Osteoarthritis. Bone and Osteoarthritis. Springer. 2007.

9. Magdalena Posadzy, Julie Desimpel, Filip M Vanhoenacker. Staging of Osteochondral Lesions of the Talus: MRI and Cone Beam CT. December 2017.

10. Nasnikova I.U., Morozov S.P., and Filisteev P.A.. Magnetic resonance tomography: quantitative assessment methods in articular cartilage structure analysis of in patients with osteoartrosis. Russian Electronic Journal of Radiology 1 75-81

11. Bruce C. Po.. Graphical Interface for Quantitative T1 and T2 Mapping of MRI Data (Massachusetts Institute of Technology) p 119

12. Caio A. Palma, Fabio A.M. Cappabianco, Jaime S. Ide, Paulo A.V. Miranda. Anisotropic Diffusion Filtering Operation and Limitations - Magnetic Resonance Imaging Evaluation. The International Federation of Automatic Control, Cape Town, South Africa. August 24-29, 2014.

13. Kalpana Shrivastava, Neelesh Gupta, Neetu Sharma. Medical Image Segmentation using Modified K Means Clustering. International Journal of Computer Applications (0975 – 8887) Volume 103 – No 16, October 2014.

14. V. Grau, A. U. J. Mewes, M. Alcaniz, R. Kikinis, S. K. Warfield. Improved Watershed Transform for Medical Image Segmentation Using Prior Information. IEEE Transactions on medical imaging, vol. 23, 2004.

15. Lidong Fu and Bin Zhang. A Co-Occurrence Matrix Algorithm Used for Medical Image. International Conference on Computer Science and Network Technology, 2011.